

Very late thrombosis induced by neoatherosclerosis in bioresorbable stent

Neoateroesclerosis que causa trombosis muy tardía de stent bioabsorbible

Guillem Muntané-Carol, Josep Gómez-Lara,* and Ángel Cequier

Unidad de Hemodinámica y Cardiología Intervencionista, Hospital Universitari de Bellvitge, Institut d'Investigació Biomèdica de Bellvitge (IDIBELL), Universitat de Barcelona, L'Hospitalet de Llobregat, Barcelona, Spain

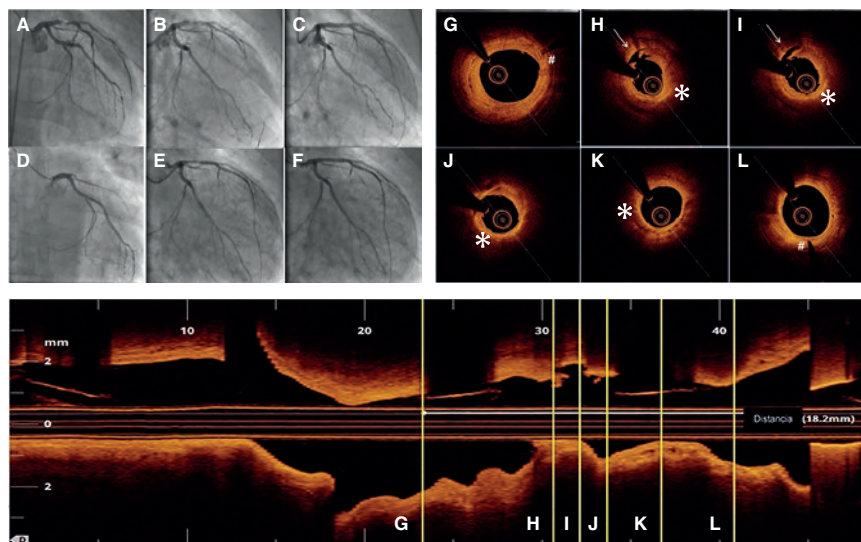


Figure 1.

Sixty-four year-old male patient with ST-segment elevation acute myocardial infarction due to occlusion of his anterior descending artery who received one 3 × 18 mm direct bioresorbable vascular scaffold (BVS) (figures 1A-C). Then he received acetylsalicylic acid and atorvastatin.

Fifty-two months later he experienced an anterior reinfarction due to the occlusion of the same segment of the anterior descending artery. Thrombo-aspiration with flow recovery (figures 1D, E) was conducted and the optical coherence tomography showed strut remnants almost indistinguishable in the BVS segment. Thrombosis was attributed to a tear in the neoatherosclerotic lipid plaque (figures 1H-I, video of the supplementary data). Figures 1G-L show the BVS markers (pound sign) and the presence of the aforementioned torn lipid plaque (asterisk and arrow, respectively). One drug-eluting metallic stent was implanted inside the stent (figure 1F).

The primary goal of BVSs is to eliminate the risk of very late thrombosis once the device is gone. In several series of very late thromboses in drug-eluting metallic stents, one of the main causes seen in the optical coherence tomography is the tear of the neoatherosclerotic lipid-laden plaque (26% to 31%). Therefore, we should expect a significant drop in stent thrombosis when the BVS process of resorption is complete. However, the restoration of geometry and the arterial vessel-motricity may promote neoatherosclerosis in patients with BVS. As far as we know, this is the very first case of ST-segment elevation acute myocardial infarction induced by a neoatherosclerotic plaque tear 4 years after BVS implantation.

SUPPLEMENTARY DATA



Supplementary data associated with this article can be found in the online version available at <https://doi.org/10.24875/RECICE.M19000018>.

* Corresponding author: Hospital Universitari de Bellvitge, Feixa Llarga s/n, 08907 L'Hospitalet de Llobregat, Barcelona, Spain.
E-mail address: gomezjosep@hotmail.com [J. Gómez-Lara].

Online: 09-05-2019.

<https://doi.org/10.24875/RECICE.M19000018>

2604-7322 / © 2019 Sociedad Española de Cardiología. Published by Permanyer Publications. This is an open access journal under the CC BY-NC-ND 4.0 license.