REC Interv Cardiol. 2021;3(2):153-154
https://doi.org/10.24875/RECICE.M20000129

Complicating a very late stent thrombosis

Complicando una trombosis muy tardía de stent

Pablo Salinas,* Pedro Martínez-Losas, Hernán Mejía-Rentería, Luis Nombela-Franco, Iván J. Núñez-Gil, and Antonio Fernández-Ortiz

Servicio de Cardiología, Hospital Clínico San Carlos e Instituto de Investigación Sanitaria del Hospital Clínico San Carlos (IdISSC), Madrid, Spain

A 61-year-old male with a drug-eluting stent (DES) implanted 5 years ago (no further information) was admitted with anterior myocardial infarction. The emergent coronary angiography performed revealed the presence of very late stent thrombosis (VLST) (figure 1A, stent in green arrows, video 1 of the supplementary data). A Sion wire (Asahi Intecc) was easily advanced, but thromboaspiration catheter failed to cross. A 2.5 mm compliant balloon that crossed easily was used to restore the flow (figure 1B, video 2 of the supplementary data). Intravascular ultrasound (IVUS) revealed the presence of proximal stent deformation (partial crush) (figure 2A, red arrows indicating crushed struts); and significant undersizing or underexpansion (average stent diameter of 2.75 mm, green arrows and 4.5 mm reference diameter, blue line, figure 2B). Stent enhancement confirmed the IVUS findings. Given the deformation of the stent and the mismatch between the stent and the vessel size, we dilated with a 4 mm non-compliant balloon (20 atm) and implanted a new 4 mm x 28 mm DES with excellent final results (figure 3, video 3 of the supplementary data). Presence of possible distal myocardial bridging.

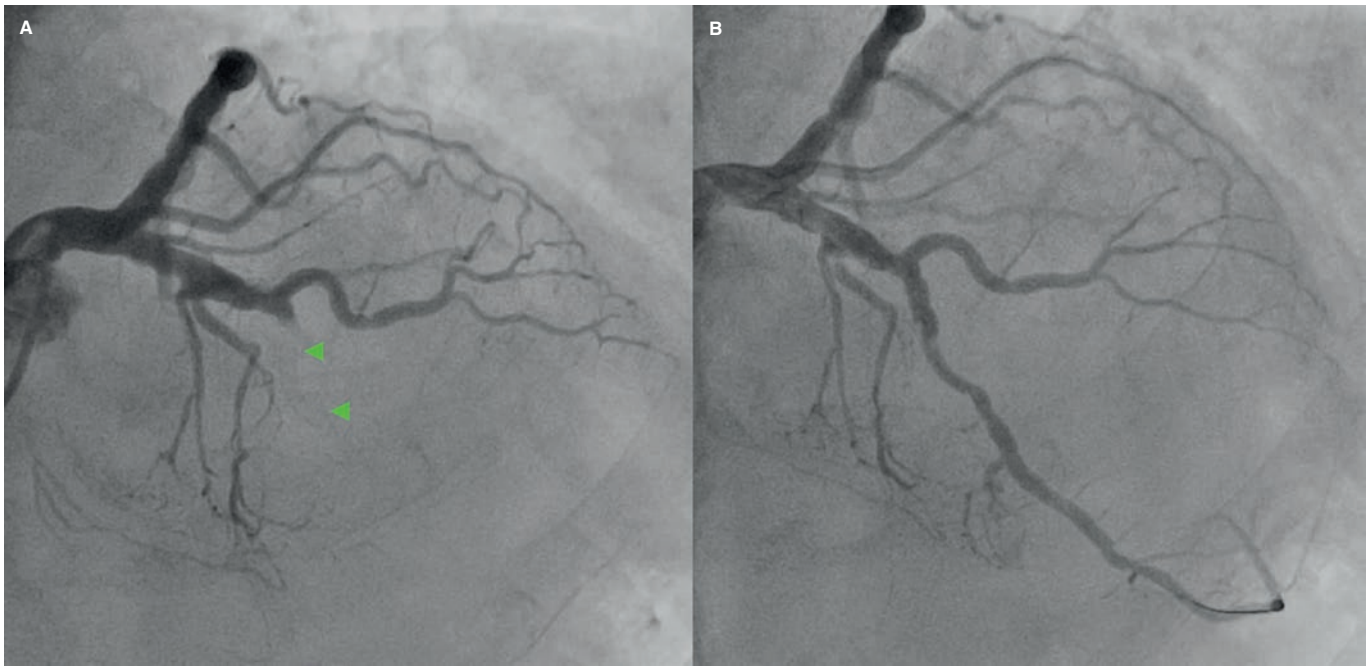

Figure 1.

* **Corresponding author:** Servicio de Cardiología, Hospital Clínico San Carlos, Prof. Martín Lagos s/n, 28040 Madrid, Spain.
E-mail address: salinas.pablo@gmail.com (P. Salinas).

Received 20 March 2020. Accepted 22 April 2020. Online: 06-09-2020.

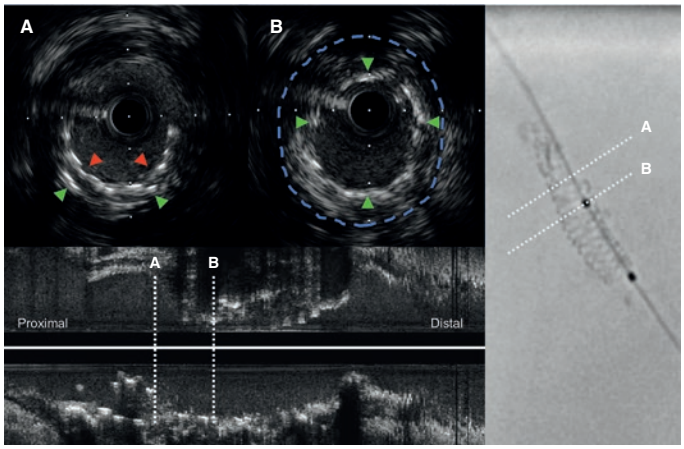

Figure 2.

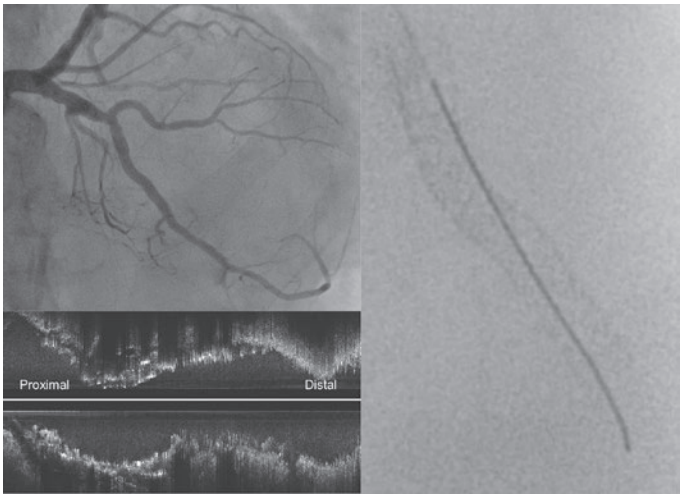

Figure 3.

Although the optical coherence tomography is the gold standard for late stent failure imaging, in selected cases, IVUS may be better for stent thrombosis. IVUS is not affected by thrombus and has higher penetration, which is critical to assess the true diameter of the vessel. In this case, the curve and malapposition facilitated an unnoticed peculiar wire crossing that facilitated the distortion of the stent. The IVUS provided essential information to assess the mechanical factors associated with VLST and successfully guide such a complex intervention. Crossing with a bent wire tip or imaging after crossing could have prevented the complication. Written informed consent was obtained from the patient for the procedure and the assignment of anonymous images for scientific dissemination.

FUNDING

No funding was received for this work.

AUTHORS' CONTRIBUTION

P. Salinas, and P. Martínez-Losas conceived and made the draft of the article. H. Mejía-Rentería, L. Nombela-Franco, and I.J. Núñez-Gil obtained, edited and made the graphic composition with the figures. A. Fernández-Ortiz conducted the critical review of the manuscript. All authors reviewed and approved the final version of the article.

CONFLICTS OF INTEREST

None.

SUPPLEMENTARY DATA

Supplementary data associated with this article can be found in the online version available at https://doi.org/10.24875/RECICE.M20000129.