In our setting it seemed reasonable for me to suggest the following percutaneous access: radial access to control the central arterial pressure with a 5-Fr pigtail catheter (it is still a mark for transseptal access), venous access to perform a transseptal puncture trying a preferably posterior puncture with the deflectable Agilis NxT introducer sheath (Abbott Cardiovascular, Sta. Clara, United States), and contralateral venous access to guide the transseptal access with an intracavitary ultrasound. Both the puncture and the regain of disc mobility can be performed through transesophageal ultrasound guidance, which also facilitates residual thrombus comparison after finishing the maneuver. The patient's clinical status is key regarding the decision of using one technique over the other. Theoretically speaking, a Judkins Right guide catheter (due to the location of the immobile disc) followed by active aspiration (a 50 mL Luer-Lock syringe directly connected to the catheter that a second operator can traction to perform the aspiration) can be used to safely cross the valve and smoothly impact the atrial surface of the prosthesis, the annulus or the disc until mobility is regained. We should not forget that the procedure should be performed with anticoagulation to keep the activated clotting time, at least, above 250 seconds in a patient operated on and who has been treated with fibrinolysis; that is why transseptal guidance seems important to me. Although according to the image the size of thrombosis seems limited, I would be suggesting protection against possible cerebral embolizations with a Sentinel device (Boston Scientific, Marlborough, MA, United States) via right radial access. Protection with a balloon inflated at left subclavian and other visceral branch level like the mesenteric branches seems optional to me given the size of the current thrombus. If the maneuver with the Judkins Right guide catheter fails, I think it would be safer to try with catheter tips of different shapes and, eventually, with a second pigtail catheter mounted over a guidewire to change the curve rather than the strategy of using guidewires to impact the discs. It is essential that the neuroradiology and angioradiology teams of our center are involved in this process.

We should mention that in the case presented here it is expected that percutaneous resolution will be a bridging therapy until the endothelization of the area of the prosthetic valve annulus can stop a third thrombosis from happening. Currently, pharmacological treatment with vitamin K antagonists is the right one. Due to the pathogenesis of this type of thrombosis where the intrinsic pathway is activated, antiplatelet therapy does not seem to play a key role and direct anticoagulants are ill-advised to prevent prosthetic valve thrombosis from happening (the REALIGN study). Finally, it is obvious that a strict clinical follow-up is required including a transesophageal ultrasound 1 month after the procedure with regular assessments of the international normalized ratio (to keep it between 3 and 3.5). The recurrence of thrombosis would make us have to rethink a third mitral valve replacement surgery and reconsider the type of prosthetic valve used. Biological valves in the mitral position are associated with a lower rate of thrombosis compared to mechanical prostheses. The downside of early degeneration in young patients should be compensated with that of recurrent prosthetic valve thrombosis. Also, thrombosis on a biological valve would be eligible for treatment with transcatheter valve implantation.[3]

FUNDING

No funding was received for this work.

CONFLICTS OF INTEREST

None declared.

REFERENCES

1. Jabbour S, Saldinger M, Alexander JC. Hemodynamic stabilisation of acute prosthetic valve thrombosis using percutaneous manipulation. *Catheter Cardiovasc Diagn.* 1996;39:e314-e316.
2. Hariram V. Percutaneous Management of Prosthetic Valve Thrombosis. *Indian Heart J.* 2014;66:427-429.
3. Unzué L, García E, Rodríguez Rodrigo FJ. Percutaneous treatment of prosthetic mitral valve thrombosis. *Rev Esp Cardiol*. 2020;73:500.

Percutaneous management of recurrent prosthetic valve thrombosis. Case resolution

Tratamiento percutáneo de trombosis valvular protésica recurrente. Resolución

Francisco Pomar Domingo,* Margarita Gudín Uriel, Pau Federico Zaragoza, Luis Martínez Ortiz de Urbina, Teresa Castelló Viguer, and Enrique Peris Domingo

Servicio de Cardiología, Hospital Universitario La Ribera, Alzira, Valencia, Spain

SEE RELATED CONTENT
https://doi.org/10.24875/RECICE.M20000132
https://doi.org/10.24875/RECICE.M20000148

* **Corresponding author:** Unidad de Hemodinámica, Servicio de Cardiología, Hospital Universitario La Ribera, Carretera de Corbera km 1, 46600 Alzira, Valencia, Spain.
E-mail address: pomar_fra@gva.es (F. Pomar Domingo).

Received 19 April 2020. Accepted 6 May 2020. Online: 22-09-2020.
https://doi.org/10.24875/RECICE.M20000133

CASE RESOLUTION

Our patient, with recurrent prosthetic valve thrombosis (PVT) and a thrombus area < 0.8 cm^2 was treated with thrombolysis but without clinical or echocardiographic improvement. It was considered that a third cardiac surgery would be too risky. Since the thrombotic load was not high, we decided to proceed with the percutaneous manipulation of the valve using the technique described by Jabbour et al.[1] in a patient with acute thrombosis of a tilting-disc aortic valve. This patient was treated with percutaneous manipulation of the disc trapped using a rigid catheter. Hariram[2] also reported on a series of 5 patients with mitral PVT and failed fibrinolytic therapy successfully treated through percutaneous manipulation of the valve using a 6 Fr-Judkins guide catheter.

In our case, the procedure was performed under general anesthesia with fluoroscopy and transesophageal echocardiography guidance. The right femoral vein was used as the access site. The transseptal puncture was performed using a Mullins introducer sheath and a Brockenbrough needle in the superior-posterior portion of the oval fossa. After the IV administration of sodium heparin (100 IU/kg) and mounted over a 0.032 in J guidewire a 3.5/6-Fr EBU guide catheter (Medtronic Launcher; Minneapolis, United States) was successfully inserted into the left atrium.

Since the disc was blocked in an almost completely closed position (video 1 of the supplementary data), we decided to take a less aggressive approach than the one described by Jabbour et al.[1] and instead of manipulating the disc with the guide catheter we decided to use a balloon catheter. Therefore, the guide catheter was mounted over a 0.014 in Balance Middleweight guidewire and advanced towards the left cavities. Although the guidewire advanced towards the left ventricle through the space left by the moving disc when opening, after several attempts it was successfully advanced through the small space left between the blocked disc and the prosthetic annulus (figure 1) (video 2 of the supplementary data). While the tip of the guidewire was resting on the apex, a 5.0 mm × 15 mm NC Euphora noncompliant

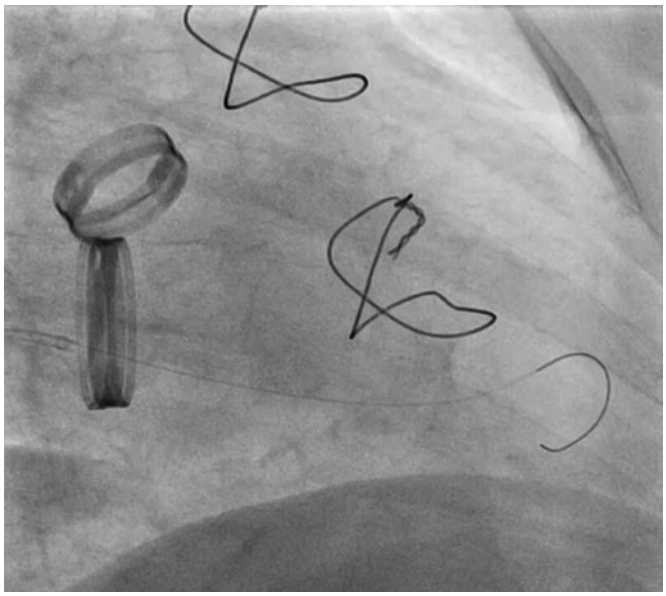

Figure 1. Guidewire entering the left ventricle.

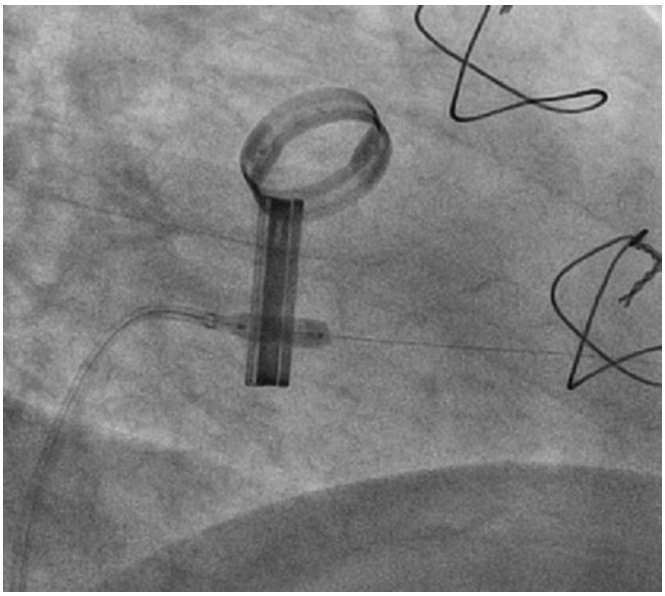

Figure 2. Balloon catheter inflated at mitral annular level.

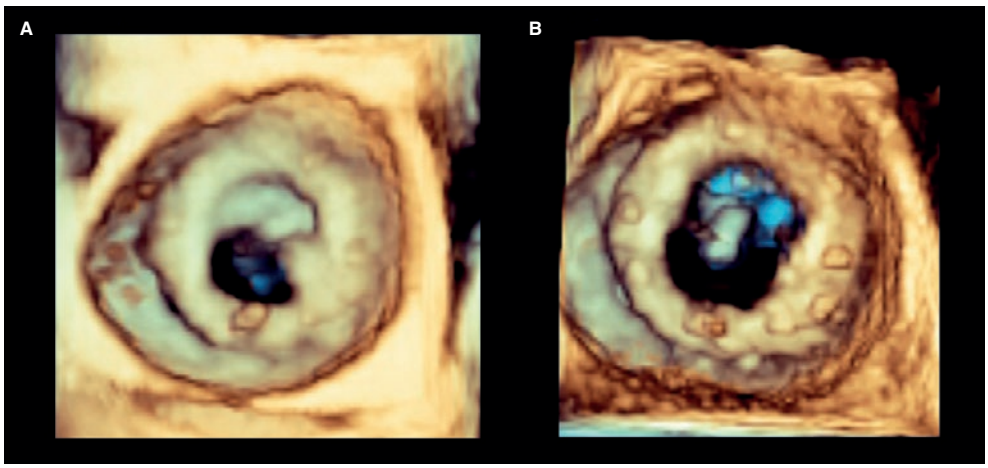

Figure 3. Mitral valve before **(A)** and after the intervention **(B)**. The complete opening of both discs can be seen after the percutaneous intervention.

balloon (Medtronic) was smoothly advanced and inflated several times at mitral annular level until the blocked disc was fully released (figure 2) (videos 3 and 4 of the supplementary data). The transesophageal echocardiography performed postprocedurally confirmed the normalization of valvular function with a mean gradient of 5 mmHg and a proper movement of both discs (figure 3). The patient was extubated immediately after the intervention without complications or further thromboembolic or hemorrhagic events. She was discharged 2 days after the procedure and remained on oral anticoagulants and acetylsalicylic acid. A systematic study conducted discarded coagulation alterations and the patient remained asymptomatic at the 12-month follow-up.

The percutaneous manipulation of a mechanical valve with PVT can be a therapeutic option in patients with low thrombotic load in whom thrombolysis is contraindicated or ineffective or in whom surgery is not feasible. However, although in our case there were no complications there is a high risk of embolic events inherent to any percutaneous manipulation of a PVT, which is why carotid filters should be considered to minimize such risk.

FUNDING

No funding was received for this work.

CONFLICTS OF INTEREST

None declared.

SUPPLEMENTARY DATA

Supplementary data associated with this article can be found in the online version available at https://doi.org/10.24875/RECICE.M20000133.

REFERENCES

1. Jabbour S, Saldinger M, Alexander JC. Hemodynamic stabilization of acute prosthetic valve thrombosis using percutaneous manipulation. *Catheter Cardiovasc Diagn.* 1996;39:314-316.
2. Hariram V. Percutaneous management of prosthetic valve thrombosis. *Indian Heart J.* 2014;66:427-429.