



## Closure of a percutaneous tricuspid paravalvular leak with the Amplatzer Muscular VSD device

### Cierre percutáneo de fuga perivalvular tricúspide con Amplatzer Muscular VSD

Noelia B. Guillén Mendoza,\* César Abelleira Pardeiro, Enrique J. Balbacid Domingo, Ángela Uceda Galiano, and Federico Gutiérrez-Larraya Aguado

Unidad de Imagen y Unidad de Hemodinámica Infantil, Servicio de Cardiología Infantil, Hospital Universitario La Paz, Madrid, Spain

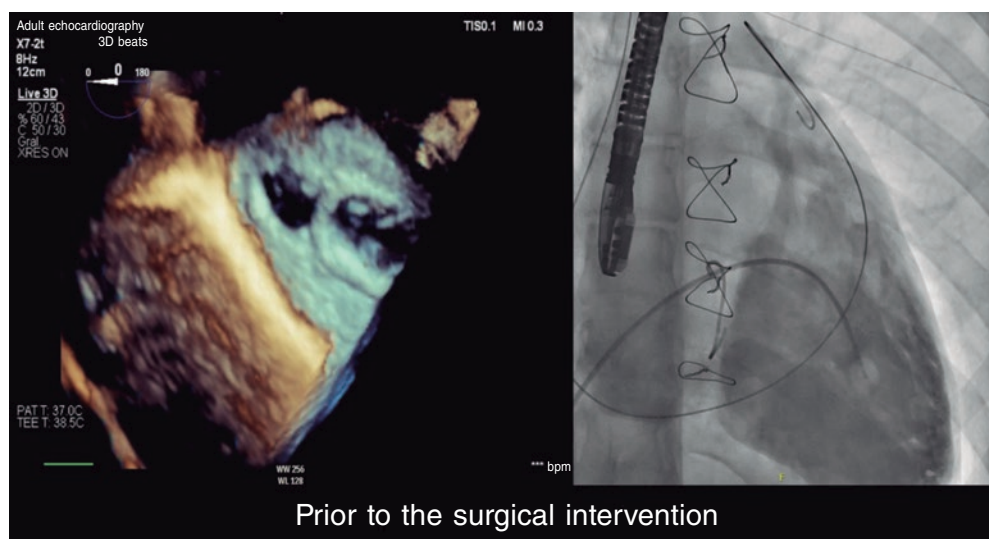


Figure 1.

We present the case of a 16-year-old girl with a prenatal diagnosis of Ebstein's anomaly and an atrial septal defect with severe tricuspid regurgitation.

In 2020, the patient was referred due to functional deterioration. Surgical repair included the implantation of a 26-mm Contour 3D tricuspid annuloplasty ring (Medtronic, United States) with the cone reconstruction technique and closure of the atrial septal defect. During the postoperative follow-up, the patient developed moderate paravalvular leak lateral to the ring that progressed to severe regurgitation with moderate right ventricular dilatation without dysfunction a year and a half later. The patient experienced no episodes of heart failure until 2 years after surgery.

Cardiac catheterization was performed via transjugular and right femoral access under general anesthesia and transesophageal echocardiography guidance, revealing the presence of a 13 mm × 10 mm leak posterolateral to the tricuspid annuloplasty ring that appeared as a 15 mm leak on ventriculography (figure 1). The first closure attempt with a 14-mm Konar MF device (Lifetech, China) did not achieve complete closure or attachment at the defect. Therefore, a second attempt was made with an 18-mm Amplatzer Muscular VSD device (Abbott, United States), which achieved proper attachment and almost complete occlusion (figure 2). After release, minimal residual regurgitation was confirmed by transesophageal echocardiography (figure 3 and video of the supplementary data). There were no irregular heart rhythms or repolarization abnormalities.

The patient was discharged 24 hours after the procedure, with the initiation of aspirin therapy. Follow-up revealed a normal electrocardiogram, with minimal residual regurgitation, and no hemolysis. The patient reported improvement during exertion.

\* Corresponding author.

E-mail address: [noelia.guillen.m@gmail.com](mailto:noelia.guillen.m@gmail.com) (N.B. Guillén Mendoza).

Received 22 May 2023. Accepted 24 August 2023. Online 13 December 2023.

2604-7322 / © 2023 Sociedad Española de Cardiología. Published by Permanyer Publications. This is an open access journal under the CC BY-NC-ND 4.0 license.

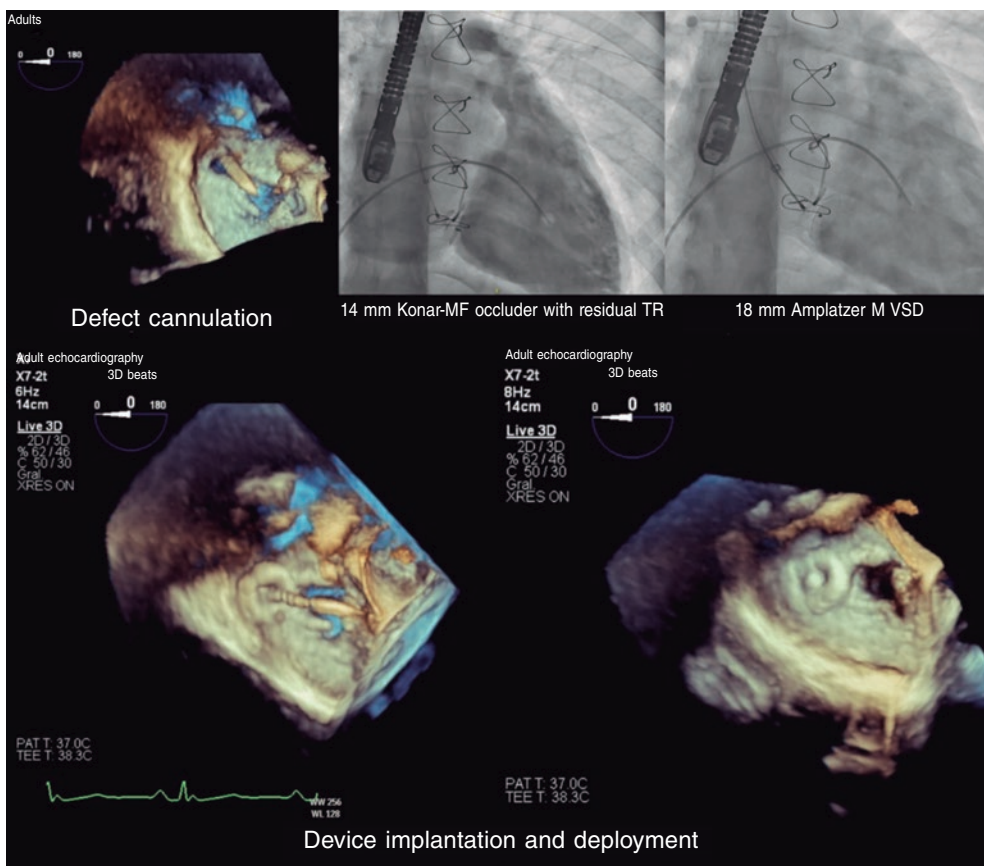


Figure 2.

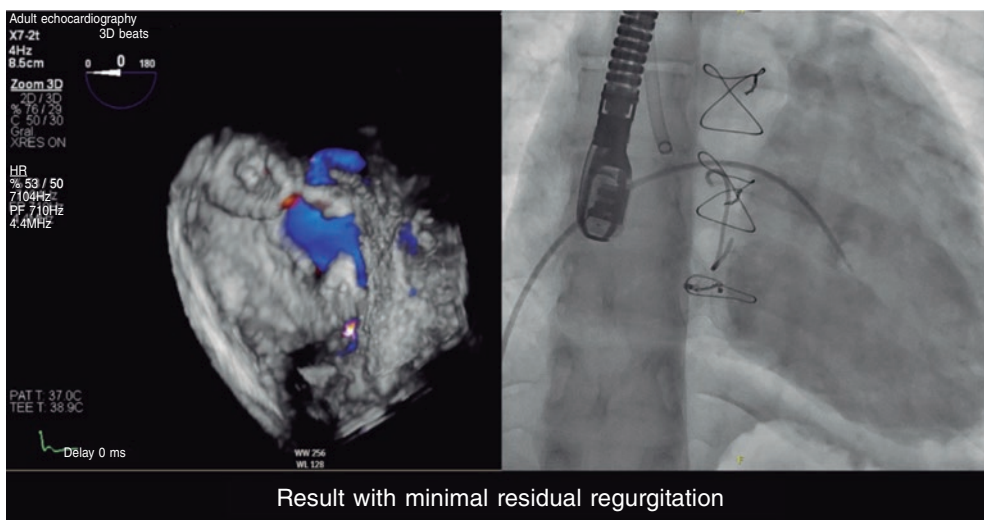


Figure 3.

### FUNDING

None declared.

### ETHICAL CONSIDERATIONS

This case was approved for publication by the pediatric cardiology unit, and did not require further evaluations by the research ethics committee. The parents of the minor and the mature minor herself gave their prior written informed consent. Because this is a presentation of an isolated case, the SAGER guidelines did not need to be followed.

### STATEMENT ON THE USE OF ARTIFICIAL INTELLIGENCE

No artificial intelligence tool has been used during the preparation of this work.

### AUTHORS' CONTRIBUTIONS

All authors participated in the procedure, image review, and manuscript drafting.

### CONFLICTS OF INTEREST

None declared.

### ACKNOWLEDGEMENTS

We wish to thank the pediatric cardiology unit at *Hospital Universitario La Paz* for their professionalism and attention to publication details. Final results are a direct consequence of their excellent patient care.

### SUPPLEMENTARY DATA



Supplementary data associated with this article can be found in the online version available at <https://doi.org/10.24875/RECICE.M23000411>.