

Stent implantation in a left ventricular assist device

Implante de stent en un dispositivo de asistencia ventricular izquierda

Raquel Álvarez Ramos,* Luis María Andrés Lalaguna, and José Luis Díez Gil

Sección de Hemodinámica y Cardiología Intervencionista, Hospital Universitari i Politècnic La Fe, Valencia, Spain

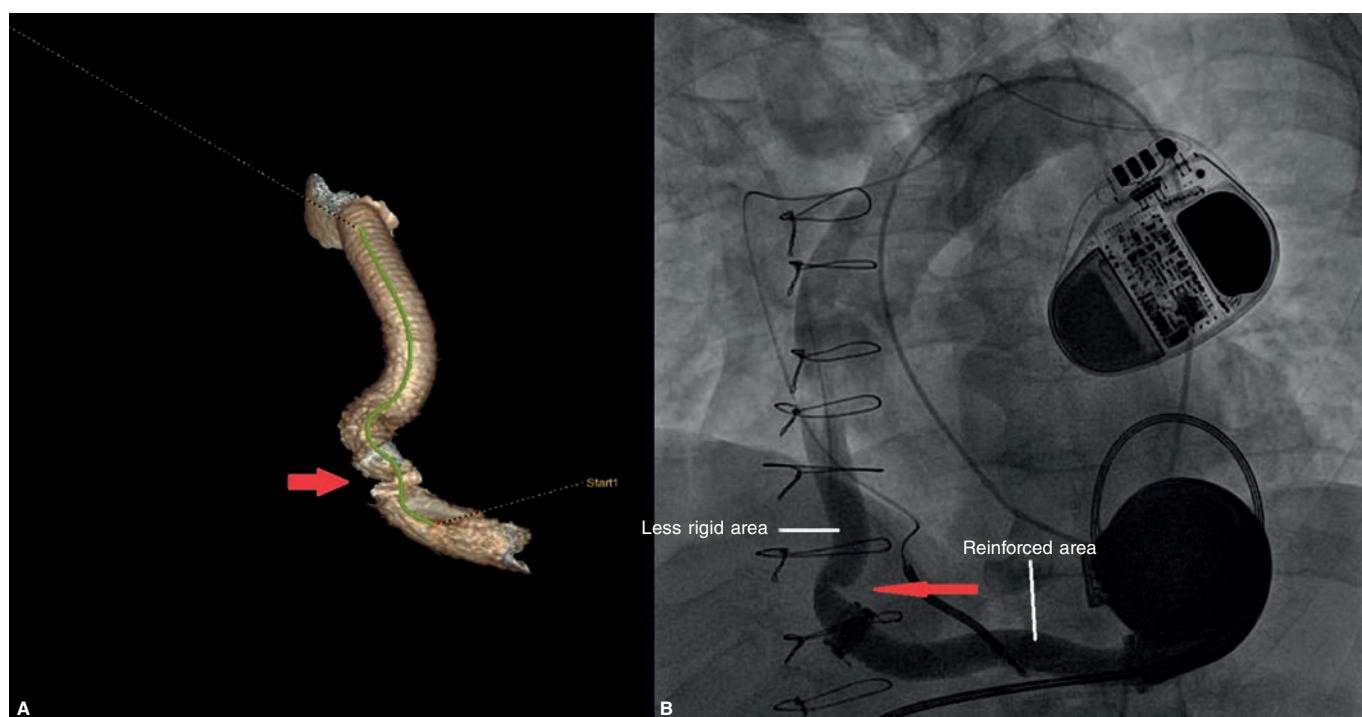


Figure 1.

Sixty-eight-year-old male patient carrier of one HeartWare left ventricular assist device as destination therapy due to ischemic dilated cardiomyopathy. Two years after the implantation, the patient experienced episodes of orthostatic hypotension consistent with low flow alerts of a few seconds duration. He also showed an impaired renal function. On suspicion of device thrombosis one computed tomography angiography was performed that revealed the shortening of the outflow cannula of the pump (figure 1A, arrow).

The interventional cardiology unit was contacted and they performed a ventriculography. The suction of contrast by the pump revealed the existence of kinking of the outflow cannula that was causing a severe stenosis in its mid-section (figure 1B [arrow] and figure 2).

Since the diameter of the cannula was known thanks the specifications established by the manufacturer (10 mm) a 10 x 57 mm BeGraft chrome-cobalt-coated stent was advanced (figure 3A) and deployed in the area of the kinking. Predilatation was performed using a 10 x 30 mm noncompliant balloon with good angiographic results (figure 3B, video 1 of the supplementary data) and normalization of the functioning parameters of the device. The patient had a favorable evolution.

* Corresponding author Sección de Hemodinámica y Cardiología Intervencionista, Hospita Universitari i Politècnic La Fe, Avda. de Fernando Abril Martorell 106, 46026 Valencia, Spain.

E-mail address: raalram@hotmail.com (R. Álvarez Ramos).

Online: 18-09-2019.

<https://doi.org/10.24875/RECICE.M19000057>

2604-7322 / © 2019 Sociedad Española de Cardiología. Published by Permanyer Publications. This is an open access journal under the CC BY-NC-ND 4.0 license.

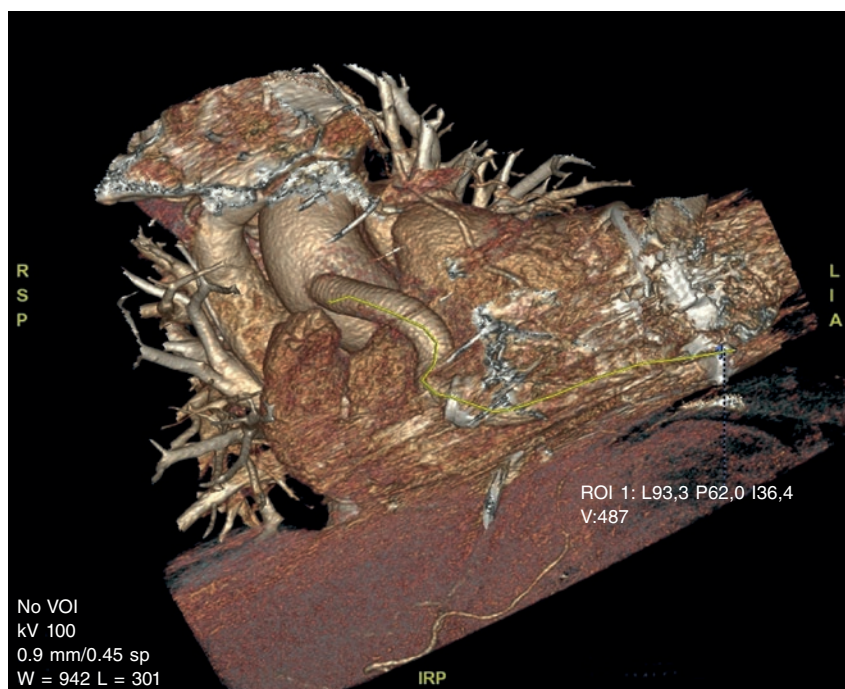


Figure 2.

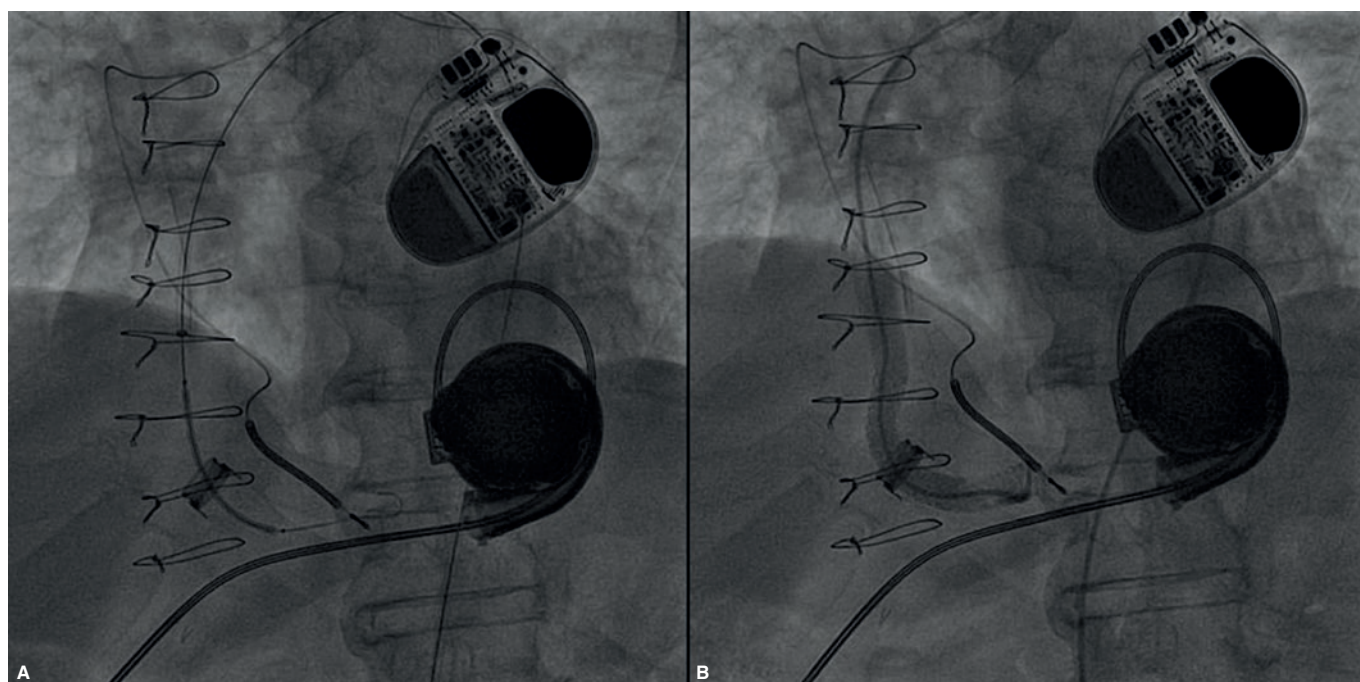


Figure 3.

Two years later the patient experienced thrombosis on the cannula proximal edge, and the cannula had to be replaced. It was confirmed that the stent was still patent.

The shortening of the outflow cannula of the left ventricular assist device is a rare complication and has poor prognosis. In this case we showed the possibility of using percutaneous therapy as an alternative to solve this complication with excellent long-term results.

SUPPLEMENTARY DATA



Supplementary data associated with this article can be found in the online version available at <https://doi.org/10.24875/RECICE.M19000057>.