REC Interv Cardiol. 2020;2(4):294-297

Clinical case

Embolization of pseudoaneurysm in Dacron subclavian-aortic graft for interrupted aortic arch repair

Embolización de seudoaneurisma en prótesis subclavio-aórtica de dacrón para la corrección de interrupción de aorta

Jesús F. García,* Nelson García, Vicente Finizola, Miguel Hidalgo, Eleazar García, and Etelvina Ceballos

Departamento de Hemodinámica, Centro Cardiovascular Regional Ascardio, Barquisimeto, Estado Lara, Venezuela

SEE RELATED CONTENT:
https://doi.org/10.24875/RECICE.M20000124
https://doi.org/10.24875/RECICE.M20000136

CASE PRESENTATION

This is the case of a 23-year-old male with a past medical history of interrupted aortic arch after left subclavian artery emergency found in the 8th month of the his life. Back in 2004, the surgical correction attempted with a subclavian-aortic graft using a Dacron graft was uneventful. The procedure resulted in an improvement of the arterial blood pressure. The anomalies associated with the initial diagnosis were the anomalous origin of the patient's right subclavian artery with an emergency following the interruption and a bicuspid aortic valve without stenosis or regurgitation. Additionally, in 2015, and due to a significant scoliosis of the spine, the patient underwent surgery with placement of screws and rods.

Back in January 2018, the patient became sick due to a massive hemoptysis that required the use of hemoderivatives. From the start the patient had a total of 17 episodes, the last one of approximately 1 liter with a reduction of hemoglobin levels down to 7 g/dL.

The patient was admitted to our center in October 2019 with a coronary computed tomography angiography performed back in April 2019 (figure 1) and in a period of 5 days. The clinical and CT scan assessment revealed the presence of a pseudoaneurysm in the anastomosis of the left subclavian artery with the Dacron graft possibly due to the dehiscence of the suture and the presence of a fistula between the aorta and the bronchi proximal to the lesion that was causing the hemoptysis. The case was studied by the heart team and the surgical option was discarded. The emergent embolization of the pseudoaneurysm was decided with the resources and equipment available in the cath lab. Pseudoaneurysms in the thoracic aorta that develop in the suture sites between the aorta and the Dacron graft are rare, but potentially lethal; they may be spontaneous, traumatic or associated with a medical procedure and, in general, require emergent surgical treatment. However, the endovascular option can be an alternative in selected cases.

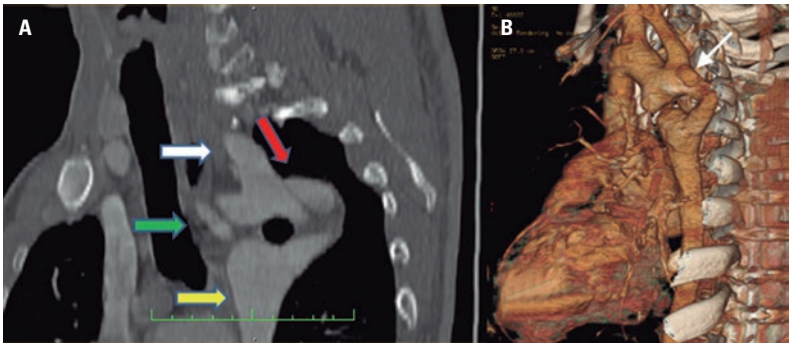

Figure 1. A: sagittal projection showing the left subclavian artery (white arrow), the pseudoaneurysm in the anastomosis of this artery with the Dacron graft (red arrow), the anomalous origin of the right subclavian artery (green arrow), and the descending thoracic aorta (yellow arrow). **B:** 3D volumetric reconstruction of the thoracic aorta revealing the location of the pseudoaneurysm (white arrow).

* **Corresponding author:** Departamento de Hemodinámica, Centro Cardiovascular Regional Ascardio, 3001 Barquisimeto, Estado Lara, Venezuela.
E-mail address: jfglmedico@gmail.com (J.F. García).

Online: 11-06-2020.
https://doi.org/10.24875/RECICE.M20000135

Embolization of pseudoaneurysm in Dacron subclavian-aortic graft for interrupted aortic arch repair. How would I approach it?

Embolización de seudoaneurisma en prótesis subclavio-aórtica de dacrón para la corrección de interrupción de aorta. ¿Cómo lo haría?

Rafael J. Ruiz Salmerón*

Servicio Endovascular, Hospital Universitario Virgen Macarena, Seville, Spain

SEE RELATED CONTENT:
https://doi.org/10.24875/RECICE.M20000135
https://doi.org/10.24875/RECICE.M20000136

HOW WOULD I APPROACH IT?

Pseudoaneurysm is defined as a partial rupture of the arterial wall that originates a fragile aneurysm sac of incomplete wall that communicates with the arterial lumen through the neck. The pseudoaneurysm of this case refers to the so-called anastomotic aneurysms (AA) that occur as a complication after surgery with synthetic valve implantation. The AA is due to the appearance of a dehiscence between the valve and the artery, which allows a pulsatile blood flow that is often contained by the fibrous reaction of surrounding tissues. The AA is not a rare entity and it is more common during the postoperative period to the point that 15 years after implanting the valve it is still present in one third of the patients, as it happened with this case.

Early AAs should lead us to think of an infectious origin. Late AAs are due to valve deterioration (specially Dacron grafts). Sometimes both causes overlap as in the case of AA fistulization towards a contaminated cavity. This is important because in the presence of an infection the endovascular solution is not possible being surgery the right option.

A high percentage of AAs are found when they are symptomatic (in this case due to aortobronchial fistulization), but even with incidental findings and given the unpredictability of the moment of rupture, treatment should be prescribed fast. In most cases this means using the endovascular option because in most cases—especially in emergent situations—surgery is often associated with a high morbimortality rate.

The imaging modality of choice to assess AA is the coronary computed tomography angiography (CCTA). In order to plan endovascular treatment, the following data should be obtained from the angiographic study:

- Location of dehiscence and aneurysm sac: proximal anastomosis, distal anastomosis or both. Relation to surrounding anatomical structures and eventual presence of fistulization. Arterial vascular anatomy in the valve juxtaposed area and, in particular, the presence of nearby bifurcation areas.
- Larger and smaller diameter of the sac; length of the neck.
- Diameter of the valve and vascular segment adjacent to the dehiscence.

The CCTA of the case shows the presence of a proximal AA of an interposed bridge graft between the aortic arch and the descending thoracic aorta. The sac has saccular morphology and discrete size with a possibly well-defined neck. The valve dehiscence is in contact with the origin of the left subclavian artery.

There are 2 endovascular approaches often used to seal a pseudoaneurysm: close the dehiscence by implanting a covered stent or fill the sac with a metal (coil) or chemical (glue) structure. In the second option the intrasaccular administration of thrombin is included too.

Thanks to its efficacy and greater simplicity, the first-line therapy to resolve an AA is often the implantation of a covered stent. The decision between a self-expandable covered stent and a balloon-expandable stent is made on 2 questions basically. The first one is whether the target area to be treated is subject to movements of flexion or a potential extrinsic compression. Nearly 90% of all AAs are found in the groin region. Here self-expandable stent should be used. The second question is the degree of precision required in the implant; balloon-expandable stents are clearly more precise.

* **Corresponding author:** Servicio Endovascular, Hospital Universitario Virgen Macarena, Avda. Doctor Fedriani 3, 41009 Seville, Spain.
E-mail address: rjruizsalmeron@yahoo.es (R.J. Ruiz Salmerón).

Online: 11-06-2020.
https://doi.org/10.24875/RECICE.M20000124

Covered stents, self-expandable stents, and balloon-expandable stents are available today. They are easy to use technically and they can be used in vessels/valves of up to 12 mm to 13 mm. For larger diameters, the devices require the use of a more complex technique. Aortic endoprostheses are considered as a self-expandable alternative and the covered Cheatham Platinum stent as a balloon-expandable stent.

As a general rule, the anchorage of the covered stent should be delivered among healthy vascular segments (whether arterial or intraprosthetic); in the case of a self-expandable stent the largest diameter of the anchorage is oversized by 1 mm and postdilatation of the stent nominal diameter is advised.

Is it possible to treat this case using a covered stent? It is not, at least it is not easily. To protect the origin of the left subclavian artery the chimney technique would be required (implantation of self-expandable covered stent from the aortic arch to the thoracic aorta with protection of a balloon-expandable stent from the left subclavian artery to the aortic arch) or else build a customized covered self-expandable prosthesis with fenestration towards the subclavian artery. The first option—more available—is limited by the large diameter of the subclavian artery, which would make it difficult to avoid the risk of leak through the self-expandable stent.

In order to consider the possibility of AA filling, the use of glue (cyanoacrylate) an even thrombin (often through percutaneous administration although it can also be administered through a microcatheter, personal experience) has been reported. With both the sac can be sealed immediately. The lack of control during their delivery and, therefore, their potential distal embolization is an important limitation here. In our own experience, these are the perfect agents to occlude pseudoaneurysms in distal vessels or in situation of multiple afferent and efferent vessels to the aneurysm sac, but this was not the case.

«Sac packing» the pseudoaneurysm with a coil can be the best option in this case, especially because the size of the sac is discrete, and the neck seems small. The stability during delivery recommends the use of a telescopic technique (5-6-Fr/90 cm guide catheter, 5-Fr Bernstein diagnostic catheter, and microcatheter). However, the secret for a proper coil embolization is to properly select the first coil: its diameter should be nominal to the sac largest diameter (it is very important to avoid excessive oversizing that may rupture its frail wall) and always larger than the diameter of the neck (to minimize the risk of embolization) with the largest possible length to occupy the maximum volume of the pseudoaneurysm. It is advised that the first coil should be a controlled delivery coil to keep all the repositioning options open. The first coil is followed by others to fill in the holes and complete the packing.

Embolization of pseudoaneurysm in Dacron subclavian-aortic graft for interrupted aortic arch repair. Case resolution

Embolización de seudoaneurisma en prótesis subclavio-aórtica de dacrón para la corrección de interrupción de aorta. Resolución

Jesús F. García,* Nelson García, Vicente Finizola, Miguel Hidalgo, Eleazar García, and Etelvina Ceballos

Departamento de Hemodinámica, Centro Cardiovascular Regional Ascardio, Barquisimeto, Estado Lara, Venezuela

SEE RELATED CONTENT:
https://doi.org/10.24875/RECICE.M20000124
https://doi.org/10.24875/RECICE.M20000135

CASE RESOLUTION

The patient was referred to the cath lab. The high left brachial artery access was tried using the dissection technique due to significant stenosis of the distal brachial artery as a consequence of an aortography performed during the patient's childhood with the Sones technique. General anesthesia with selective orotracheal intubation was used. A 6-Fr Cobra-type guide catheter was advanced and entered the pseudoaneurysm. An early injection was used for its catheterization (video 1 and video 2 of the supplementary data) (neck: 8.4 mm; base: 2.9 × 1.5 cm). Three fiber coils (6 mm with 5 turns) were deployed in the base of the pouch (figure 1). Afterwards, a 5 × 4 mm Amplatzer

* **Corresponding author:** Departamento de Hemodinámica, Centro Cardiovascular Regional Ascardio, 3001 Barquisimeto, Estado Lara, Venezuela.
E-mail address: jfglmedico@gmail.com (J.F. García).

Online: 11-06-2020.
https://doi.org/10.24875/RECICE.M20000136

ADO II device was positioned and delivered in the pseudoaneurysm neck. The persistence of the passage of contrast to the pouch was evident and it was decided to deliver another 6.5 mm fiber coil with 3 turns to finish the pseudoaneurysm neck sealing (figure 2, video 3 of the supplementary data). One month after the procedure, the patient had a new episode of hemoptysis. The coronary computed tomography angiography performed confirmed the patency of the pouch in its proximal portion, which is why the patient underwent a second procedure. This time the procedure was performed under local anesthesia using the brachial dissection technique, a 6-Fr Cobra-type guide catheter, and pouch embolization with Interlock 2D coils of 20 and 8 cm. The complete filling of the pseudoaneurysm was secured (figure 3, video 4 of the supplementary data).

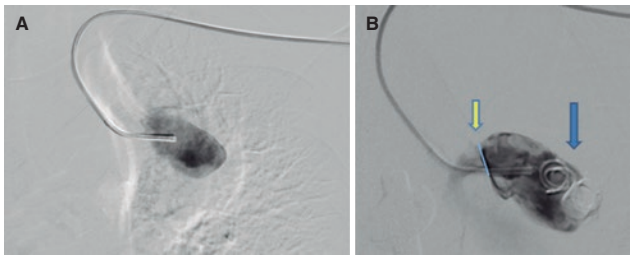

Figure 1. A: anteroposterior projection showing the trajectory of the catheter until it enters the pseudoaneurysm. **B:** right anterior oblique projection at 20º showing 3 fiber coils occupying a third of the base of the pouch (blue arrow); additionally, flowback is seen indicative of the pseudoaneurysm neck (yellow arrow).

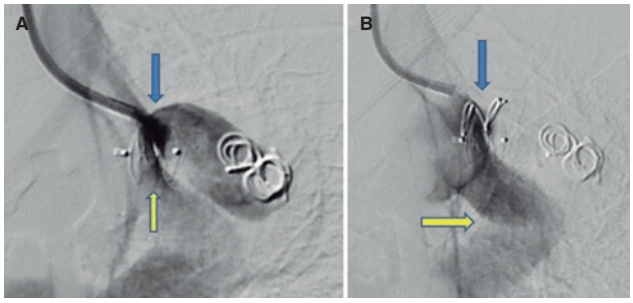

Figure 2. A: right anterior oblique projection at 20º showing the Amplatzer device partially sealing the neck (yellow arrow). An endoleak seen above the device that keeps filling the pseudoaneurysm (blue arrow). **B:** fiber coil sealing the endoleak (blue arrow) and subclavian-aortic bypass with Dacron graft (yellow arrow).

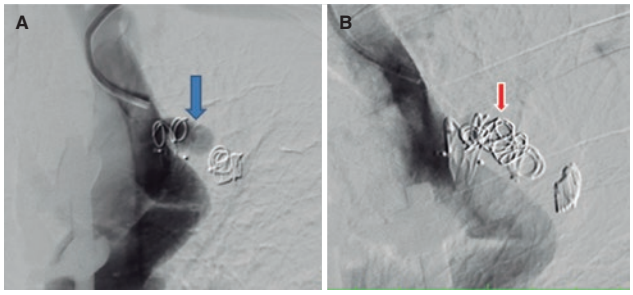

Figure 3. A: left anterior oblique projection at 20º. The blue arrow shows the endoleak partially filling the pouch. **B:** left anterior oblique projection at 30º. The red arrow shows the Interlock coils totally occupying the pouch.

Pseudoaneurysms are due to the rupture of 1 of the layers of the vessel wall that is contained by the remaining layers of the wall and adjacent structures. In general, it is often corrected through surgery. The endovascular resolution of this condition with the use of coils or other devices is not a common thing in the medical literature; however, it is a valid option for selected cases. This time, such technique was decided because of the urgent need to solve the case and considering the material and equipment available at our center. The use of covered stents to correct coarctations of aorta or interruptions of the aortic arch due to nearby aneurysms or pseudoaneurysms has been reported in the medical literature; however, in this particular case, the proximity of both subclavian arteries required a bilateral carotid-subclavian bypass before deploying the endoprosthesis followed by left subclavian artery embolization, which would delay the procedure.

SUPPLEMENTARY DATA

Supplementary data associated with this article can be found in the online version available at https://doi.org/10.24875/RECICE.M20000136.