



# All for one or one for all!

*¡Todos para uno o uno para todos!*

A. John Camm\*

Department of Molecular and Clinical Sciences, City St. George's University of London, London, United Kingdom

SEE RELATED CONTENT:

<https://doi.org/10.24875/RECICE.M25000507>

Atrial fibrillation (AF) is a common arrhythmia with an incidence rate of approximately 2% of the general population in the developed world. It is usually a consequence of underlying cardiovascular or thoracic morbidities, cardiovascular stress, toxicities, or age-related degeneration. The presence of AF may provoke or aggravate cardiocerebrovascular disease, resulting in stroke, dementia, worsening heart failure, disturbances of mood and quality of life. Thromboprophylaxis is a fundamental and critical element of its management.

Warfarin, the most widely used oral vitamin K antagonist (VKA), was first used clinically during the 1950s but its application for stroke prevention in patients at risk of AF-related thromboembolism only became clinically commonplace after the metanalysis of early trials vs placebo, or the then standard of care. This showed a remarkable stroke reduction of 64% and an often forgotten 26% reduction of mortality, which favored anticoagulation.<sup>1</sup> There is, however, one major problem: major bleeds are common (2%-3% per year), of which intracranial bleeding (1% per year) often causes more serious strokes than those of ischaemic etiology. Major haemorrhage is usually due to an underlying arteriopathy and/or excessive anticoagulation due to drug-drug and food-drug interactions increasing the anticoagulant potency of the VKA. Regular monitoring of the anticoagulation status is necessary, and patient education/counseling is needed to encourage patient adherence and persistence with therapy. Both patients and doctors often prefer to use the considerably less effective approach using aspirin, despite its associated bleeding risks.

Direct oral anticoagulants (DOACs), which are at least equally effective and less complicated by intracranial bleeds, entered the therapeutic armamentarium in 2010.<sup>2</sup> Dosing depends to a certain degree on a few patient characteristics, such as renal function, age and body weight. They are not compromised by food-drug interactions but co-medication with P-glycoprotein inhibitors does result in elevated plasma concentrations. DOACs do not need regular monitoring. As a class effect, the risk of major gastrointestinal bleeding is 25% higher, and clinically relevant non-major bleeding remains a frequent and troublesome concern. It does not come as a surprise, then, that many patients continue to be reluctant to accept anticoagulant therapy to avert a future, albeit serious event.

Drug doses are often skipped, and discontinuation is a common finding.<sup>3</sup>

Some patients are at high risk of bleeding complications, regardless of which anticoagulant is being used, and others remain vulnerable to ischaemic stroke, even when the anticoagulant is properly prescribed and appropriately taken. Since most AF-related thrombi form in the left atrial appendage (LAA) a mechanical approach, such as excising, closing or occluding the appendage is a therapeutic option. When patients with high-stroke-risk AF undergo cardiac surgery, many surgeons routinely excise the LAA as a preventive measure. For other patients the LAA may be closed with a ligature inserted transcutaneously. However, for most patients at high risk of AF-related stroke for whom a mechanical solution is thought necessary, an occlusion device may be inserted transvenously and placed through the atrial septum and into the LAA. Following device insertion, antiplatelet drugs or full or reduced-dose anticoagulants are used to prevent thrombus formation on the newly implanted foreign body. Although the therapy has proven to be as effective as VKA anticoagulation<sup>4</sup> and is possibly, at least, as effective as DOAC therapy,<sup>5</sup> this remains to be conclusively proven by randomized clinical trials.

The Left Atrial Appendage Occlusion Study (LAAOS III) has conclusively demonstrated that removing/ligating the orifice of the LAA is very effective at reducing stroke or systemic embolism in patients with high-risk AF who undergo surgery for coronary revascularization or heart valve surgery.<sup>6</sup> However, almost 80% of the patients from the study were also still on anticoagulants 3 years after surgery, which raises the question about whether the most effective stroke-reducing therapy for patients with high-risk AF, not undergoing surgery, should also be a combination of oral anticoagulation and LAAC (left atrial appendage closure) with a mechanical device. It does not come as a surprise that a new study (LAAOS IV) recruiting AF patients at high risk of stroke despite anticoagulation (CHA<sub>2</sub>DS<sub>2</sub>-VASc score  $\geq 4$ ) will compare anticoagulation with anticoagulation plus a mechanical device.<sup>7</sup> (LAAOS IV - Research Studies - PHRI - Population Health Research Institute of Canada).

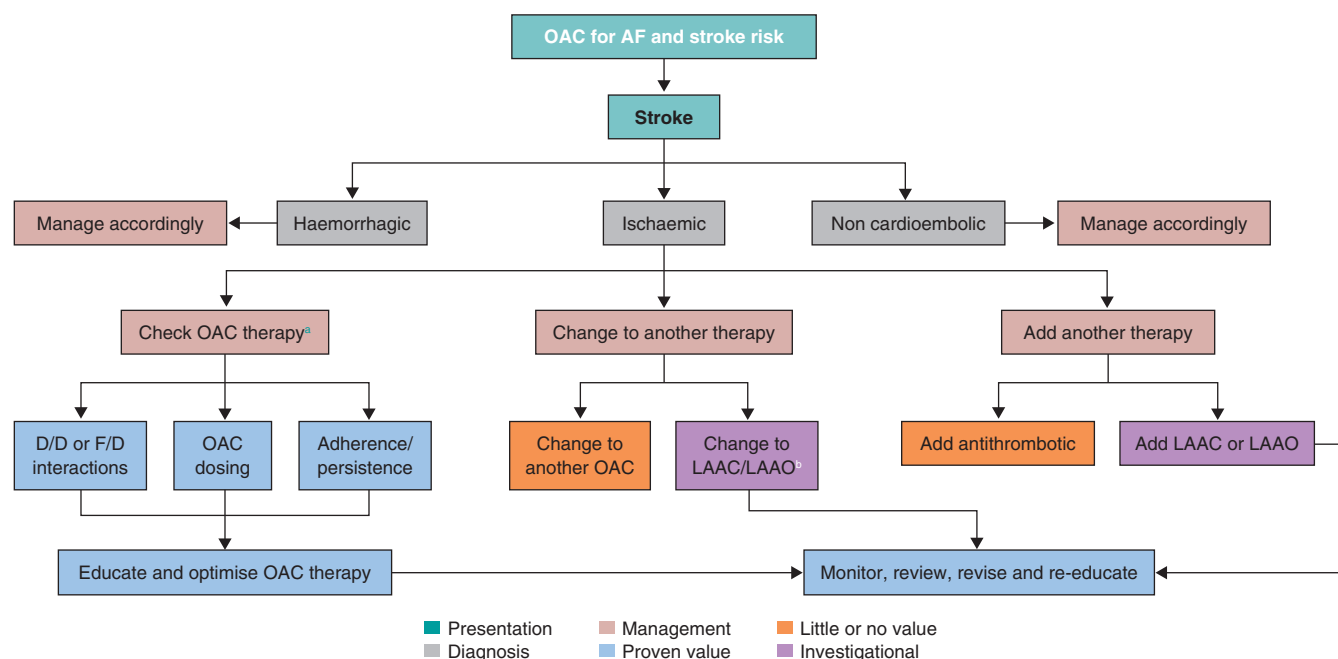
In a recent paper published in *REC: Interventional Cardiology*, Amaro et al. described their study which is also designed to address

\* Corresponding author.

E-mail address: [jcammm@citystgeorges.ac.uk](mailto:jcammm@citystgeorges.ac.uk) [A.J. Camm].

Online 16 May 2025.

2604-7322 / © 2025 Sociedad Española de Cardiología. Published by Permanyer Publications. This is an open access journal under the CC BY-NC-ND 4.0 license.



**Figure 1.** Approach to patients with atrial fibrillation who suffer a stroke whilst treated with an anticoagulant. AF, atrial fibrillation; D/D, drug-drug; F/D, food-drug; LAAC, left atrial appendage closure; LAAO, left atrial appendage occlusion; OAC, oral anticoagulants.

<sup>a</sup> Direct oral anticoagulants drug level/coagulation tests of limited value with short acting medications.

<sup>b</sup> Plus short term OACs, longer term aspirin or dual antiplatelet therapy, or low dose of direct oral anticoagulants.

this issue, choosing a specific group of patients who have suffered a stroke despite anticoagulation (breakthrough stroke).<sup>8</sup> Although this is not a rare event with an incidence rate is 1%/year in anticoagulated patients due to AF, there is no accepted and fully investigated therapeutic solution to this clinical problem (figure 1). If the stroke is ischaemic and cardioembolic it is likely related directly to the AF (3 of 4 breakthrough strokes). Anticoagulant therapy might not have been prescribed or taken correctly, which can be improved. If current antithrombotic therapy seems optimal, as in the proposed study by Amaro et al.<sup>8</sup>, physicians sometimes consider changing the anticoagulant, increasing VKA to an INR > 3.0, using an off-label high dose of a DOAC, or adding antiplatelet therapy like aspirin—none of which appear beneficial. In these circumstances, a practical solution may be switching to a mechanical device requiring a short course of antiplatelet therapy or low-dose anticoagulation, or adding a mechanical device to the existing anticoagulant regimen. Although none of these approaches has been fully demonstrated, substantial observational data<sup>9-11</sup> support transitioning from anticoagulation to LAAC therapy, justifying ongoing randomized clinical trials in this patient population. These trials compare LAAC therapy to anticoagulant treatment, or to no thromboprophylaxis if patients with bleeding complications associated with oral anticoagulants are also eligible for enrollment. The results of the OCCLUSION-AF PROBE design trial, with 750 patients and documented AF and ischaemic strokes or transient ischaemic attacks randomized to DOAC or LAAC are expected shortly.<sup>12</sup>

There is some observational study support for the hybrid approach of adding LAAC to inadequate anticoagulant therapy, a strategy for preventing a recurrence of oral anticoagulation-resistant cardioembolic stroke in patients with AF and no major oral anticoagulation-related bleeding complications.<sup>13</sup> Several groups have proposed and are conducting such studies, such as the ELAPSE trial (Early closure of left atrial appendage for patients with atrial fibrillation and ischaemic stroke despite anticoagulation therapy; NCT05976685)

which will help them, together with the ADD-LAAO study (Oral anticoagulation alone vs oral anticoagulation plus left atrial appendage occlusion in patients with stroke despite ongoing anticoagulation) led by Amaro et al. to confirm or refute the value of this hybrid approach. Successful results of these studies would help us widen extensively the indication for LAAC therapy, which is now a procedure that can be performed by skilled operators with a complication rate no greater than that of other common procedures in interventional cardiology.<sup>14</sup>

This strategy of using all antithrombotic approaches may be more effective therapy for patients resistant to just one strategy.

## FUNDING

None declared.

## CONFLICTS OF INTEREST

A.J. Camm has received personal fees from Acesion, Anthos, Incarda, Milestone, Abbott, Boston Scientific and Johnson and Johnson.

## REFERENCES

- Hart RG, Pearce LA, Aguilar MI. Meta-analysis: antithrombotic therapy to prevent stroke in patients who have nonvalvular atrial fibrillation. *Ann Intern Med.* 2007;146:857-867.
- Ruff CT, Giugliano RP, Braunwald E, et al. Comparison of the efficacy and safety of new oral anticoagulants with warfarin in patients with atrial fibrillation: a meta-analysis of randomised trials. *Lancet.* 2014;383: 955-962.
- Ozaki AF, Choi AS, Le QT, et al. Real-World Adherence and Persistence to Direct Oral Anticoagulants in Patients With Atrial Fibrillation: A Systematic Review and Meta-Analysis. *Circ Cardiovasc Qual Outcomes.* 2020;13:e005969.

4. Reddy VY, Doshi SK, Kar S, et al. 5-Year Outcomes After Left Atrial Appendage Closure: From the PREVAIL and PROTECT AF Trials. *J Am Coll Cardiol.* 2017;70:2964-2975.
5. Osmancik P, Herman D, Neuzil P, et al. 4-Year Outcomes After Left Atrial Appendage Closure Versus Nonwarfarin Oral Anticoagulation for Atrial Fibrillation. *J Am Coll Cardiol.* 2022;79:1-14.
6. Whitlock RP, Belley-Cote EP, Paparella D, et al. Left Atrial Appendage Occlusion during Cardiac Surgery to Prevent Stroke. *N Engl J Med.* 2021;384:2081-2091.
7. Jolly SS. Surgical Left Atrial Appendage Occlusion and Rationale for design of LAAOS IV. In: CRT 2023. 2023 Feb 25-28; Washington DC. Available at: [https://phri.ca/wp-content/uploads/2023/04/LAAOS-4\\_FDA.pdf](https://phri.ca/wp-content/uploads/2023/04/LAAOS-4_FDA.pdf). Accessed 9 Apr 2025.
8. Amaro S, Cruz-González I, Estévez-Loureiro R, et al. Left atrial appendage occlusion plus oral anticoagulation in stroke patients despite ongoing anticoagulation: rationale and design of the ADD-LAAO clinical trial. *REC Interv Cardiol.* 2025;7:140-145.
9. Korsholm K, Valentin JB, Damgaard D, et al. Clinical outcomes of left atrial appendage occlusion versus direct oral anticoagulation in patients with atrial fibrillation and prior ischemic stroke: A propensity-score matched study. *Int J Cardiol.* 2022;363:56-63.
10. Abramovitz Fouks A, Yaghi S, Selim MH, Gökçal E, Das AS, Rotschild O, Silverman SB, Singhal AB, Kapur S, Greenberg SM, Gurol ME. Left atrial appendage closure in patients with atrial fibrillation and acute ischaemic stroke despite anticoagulation. *Stroke Vasc Neurol.* 2025;10:120-128.
11. Cruz-González I, González-Ferreiro R, Freixa X, et al. Left atrial appendage occlusion for stroke despite oral anticoagulation (resistant stroke). Results from the Amplatzer Cardiac Plug registry. *Rev Esp Cardiol.* 2020;73:28-34.
12. Korsholm K, Damgaard D, Valentin JB, et al. Left atrial appendage occlusion vs novel oral anticoagulation for stroke prevention in atrial fibrillation: rationale and design of the multicenter randomized occlusion-AF trial. *Am Heart J.* 2022;243:28-38.
13. Maarse M, Seiffge DJ, Werring DJ, et al. Left atrial appendage occlusion vs standard of care after ischemic stroke despite anticoagulation. *JAMA Neurol.* 2024;81:1150-1158.
14. Kapadia SR, Yeh RW, Price MJ, et al. Outcomes With the WATCHMAN FLX in Everyday Clinical Practice From the NCDR Left Atrial Appendage Occlusion Registry. *Circ Cardiovasc Interv.* 2024;17:e013750.